



Přehledový článek | Review article

Complications of catheter ablation for atrial fibrillation**Bashar Aldhoon, Josef Kautzner***Klinika kardiologie, Institut klinické a experimentální medicíny, Praha, Česká republika*

INFORMACE O ČLÁNKU:

Historie článku:

Došel do redakce: 18. 10. 2012

Přijat: 9. 11. 2012

Dostupný online: 16. 11. 2012

Keywords:

Atrial fibrillation

Catheter ablation

Complication

Klíčová slova:

Fibrilace síní

Katetrizační ablace

Komplikace

ABSTRACT

Catheter ablation of atrial fibrillation is a modern therapeutic method that effectively prevents arrhythmia recurrences. Because of the complexity nature of this procedure, it is not surprising that the rate of complications is higher compared with other types of catheter ablations. This review focuses on the most important complications, and discusses their prevention, diagnosis, and therapy.

SOUHRN

Katetrizační ablace fibrilace síní je moderní léčebná metoda, která účinně brání recidivám fibrilace síní. Tento komplexní výkon je ve srovnání s ostatními ablačními výkony spojen s vyšším výskytem potenciálně závažných komplikací. Tento přehled se zabývá nejvýznamnějšími komplikacemi, jejich prevencí, diagnostikou a léčbou.

© 2012, ČKS. Published by Elsevier Urban and Partner Sp. z o.o. All rights reserved.

Introduction

Over the past decade, catheter ablation has emerged as an effective treatment option for treatment of patients with symptomatic paroxysmal or persistent atrial fibrillation (AF). Because of the complex nature of the procedure, there is an increased risk of various complications that can occur during or after the procedure. Compared with other ablation procedures, catheter ablation of AF has its own characteristics that explain some specific complications. Multiple vascular accesses, high doses of anti-coagulation agents, transeptal puncture and long ablation time are characteristic attributes. In addition, the left atrial wall is a thin structure that is surrounded by other structures such as esophagus. This explains potential for damage of the left atrial wall or esophageal wall. Despite

continuous efforts to improve safety, the incidence of major complications, usually defined as a complication that results in permanent injury or death, requires intervention or prolongs or requires hospitalization [1], is still relatively high. Understanding the pathogenesis and risks of the procedure, as well as operator's experience are factors that help to minimize complications. This review describes known complications of catheter ablation of AF and provides insights into the evolving strategies to minimize these complications.

Incidence of complications in AF ablation

The incidence of complications associated with selective ablation for AF ranges in several registries between 3.9%

Adresa: MUDr. Bashar Aldhoon, Ph.D., Klinika kardiologie, Institut klinické a experimentální medicíny, Vídeňská 1958/9, 140 21 Praha 4,
e-mail: bashar.alldhoon@ikem.cz

DOI: 10.1016/j.crvasa.2012.11.006

Table 1 – Type and prevalence of complications related to AF ablation in selected single high-volume centers.

	Spragg et al. (n = 641)	Dagres et al. (n = 1,000)	Baman et al. (n = 1,642)	Hoyt et al. (n = 1,190)
Thromboembolic events	1.1%	0.4%	0.2%	1.1%
Cardiac tamponade	1.2%	1.3%	1.2%	1.1%
Vascular complications	1.7%	1.3%	1.9%	1.5%
Pulmonary vein occlusion	0.1%	0.1%	0.01%	0.1%
Atrio-esophageal fistula	none	0.2%	none	none
Heart block	0.1%	none	none	0.1%
Acute lung injury	0.1%	none	none	none
Mitral valve injury	0.1%	none	none	0.1%
Endocarditis	none	0.2%	none	none
Deep vein thrombosis	none	0.1%	0.01%	none
Transient phrenic nerve injury	none	none	none	0.1%
Aspiration	none	0.2%	none	none
Death of unclear cause	none	0.2%	none	none
Overall rate of complications	5%	3.9%	3.5%	4.7%

and 6% [2–4]. This variation in incidence of complications reflects the learning curve period and different adopted technology and strategies in different centers. Data from recent worldwide survey reported an overall incidence of complications of 4.5% with fatal outcome in 0.15% [3]. Data from high-volume single centers reported similar incidence of major complications (Table 1). The most recent data that reflect real life scenario come from the European EORP Pilot registry with overall complication rate of 7.7%, of which 1.7% was major [5]. The most frequent are vascular complications (pseudoaneurysms, arteriovenous fistulas, and hematomas), cardioembolic events (stroke and transient ischemic attacks), and pericardial perforation (effusion/tamponade). The latter, together with rare atrio-esophageal fistula, is the major cause of possible fatal outcome.

Thromboembolic complications

Thromboembolism is one of the most serious complications of AF ablation. The incidence of periprocedural thromboembolic events varies from 1% to 7%, depending on the ablation strategy and anticoagulation regimen used in this period [3,6]. In one study, a high incidence of silent cerebral thromboembolism following AF ablation has also been reported, however, its clinical impact is still not clear [7].

It is important to emphasize that each patient with AF has a baseline risk for a thromboembolic event that can be estimated by indices such as the CHA₂DS₂-VASc score [8]. Catheter ablation could further temporarily increase the risk of thromboembolic events. A number of risk factors for the development of thromboembolic complications have been proposed. These include persistent activation of the coagulation cascade due to intravascular placement of catheters [9] and endothelial disruption resulting from ablation [10], cardioversion during AF abla-

tion [7], impairment of normal left atrial (LA) contraction or “atrial stunning” [11] and reduction in the LA transport function [12], ablation of persistent AF [13], and finally anticoagulation swing between warfarin through low-molecular-weight heparin (LMWH) to intravenous heparin and back to oral anticoagulation [14].

Thromboembolic events can occur during ablation procedure or within a period up to 2 weeks after ablation. The clinical manifestation varies according to location of the involved arterial bed. The most feared is intracranial embolism leading to stroke. Less common is coronary artery and/or peripheral embolization. Cerebral embolization is usually treated conservatively with heparin, whereas, in peripheral embolization surgical embolectomy is also recommended.

Anticoagulation therapy during pre-, peri- and post-ablation period is the cornerstone of prevention strategy for thromboembolic events. Trans-esophageal echocardiography (TEE) is recommended in intermediate- to high-risk patients prior to procedure to exclude preformed thrombus in the LA. However, we learned from previous practice of using intracardiac echocardiography (ICE) that introducing needle or sheath into LA may quickly trigger a new thrombus formation. Because of this experience, we adopted a strategy of administering intravenous heparin at the beginning of the ablation procedure – well before the first transseptal puncture. Additionally, intra-procedural TEE or ICE can be helpful in stratifying high-risk patients with smoke-like echogenicity in the LA. In these patients, a more aggressive anticoagulation regimen should be considered to prevent LA thrombus formation [15]. ICE may also help in an early detection of thrombus in LA during the procedure (Fig. 1).

Until recently, warfarin was usually stopped 3 days prior to the procedure and “bridged” with LMWH. However, several reports on periprocedural therapeutic anticoagulation with warfarin showed a reduced risk of periprocedural stroke without increased bleeding compli-

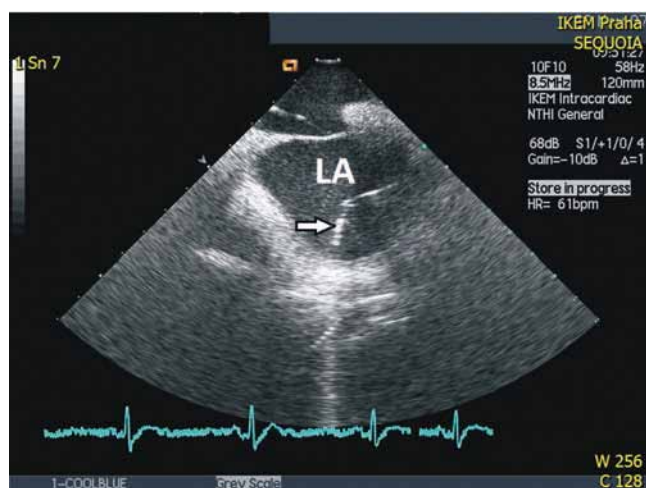


Fig 1. – Lasso catheter introduced into the left atrium (LA) shown by ICE. At the end of the catheter is seen fluttering thrombus (arrow).

cations [16,17]. This has resulted in a new trend towards performing ablation without interruption of warfarin therapy. In the event of major bleeding an activated factor VII can be infused to rapidly reverse the effects of warfarin. Accordingly, we have modified our strategy of anticoagulation therapy and perform ablation procedures on uninterrupted warfarin therapy with INR in the range of 2–2.5.

Recently, new anticoagulant agents, including thrombin inhibitor and factor Xa inhibitor, have been introduced into clinical practice. However, experience with catheter ablation on this anticoagulation regimen is still very limited. In a recent published study, Lakkireddy et al. found a higher incidence of bleeding and pericardial effusions in patients treated with dabigatran and no difference in the rate of thromboembolism compared with warfarin [18].

Air embolism

Other less frequent reason for embolic events is air embolism that can occur mainly during introduction or flushing transseptal sheaths. The preferential localization for air emboli is right coronary artery territory due to the most superior position of the arterial ostium in the supine patient. Clinical presentation includes transient acute inferior ischemia and/or heart block. Symptoms usually resolve within few minutes and cardiopulmonary support is rarely needed. Prevention measures include repeated and continuous flushing of sheaths and careful removal of all air bubbles from sheaths.

Cardiac tamponade

Cardiac tamponade is the other important complication that may result in a fatal outcome. Based on analysis of data from registries, it is the most frequent cause of periprocedural death occurring in association with AF ablation [6]. Although cardiac tamponade can occur in any

ablation procedure, its incidence is somewhat higher with AF ablation (0.8–2.9%) [2,4,19]. This can be attributed to the complexity of the procedure, including the common need for two or more transseptal punctures, frequent manipulation with catheters, extensive ablation, and high level of systemic anticoagulation.

Cardiac perforation leading to cardiac tamponade can occur: (1) during transseptal puncture (puncture of the right atrial posterior wall before entering the LA or puncture the roof, appendage, or lateral LA wall), (2) during catheter manipulation (tear of the LA appendage or roof of the LA), or (3) during delivery of radiofrequency energy (overheating with development of steam pop, leading to myocardial rupture). In a swine model, Eick et al. found a significant association between a sudden change in impedance and a risk of developing tamponade [20].

It should be noted that delayed cardiac tamponade, defined as cardiac tamponade occurring one hour or more following an AF ablation procedure, has also been reported [3]. Cardiac tamponade can also occur during cryoballoon ablation procedures with an overall incidence of cardiac tamponade up to 1.6% [21].

Clinically, cardiac tamponade presents either as an abrupt dramatic fall in blood pressure, or more insidiously, as a gradual decrease in blood pressure. Development of intra-procedural hypotension in any patient should be assumed to be due to tamponade until it is ruled out. A decreased excursion of the left heart border on fluoroscopy in the left anterior oblique projection is an early sign of cardiac tamponade. Diagnosis can be immediately confirmed with transthoracic echocardiography or ICE if used as part of the ablation procedure.

Once the diagnosis of cardiac tamponade confirmed, immediate percutaneous subxiphoid pericardiocentesis with placement of intra-pericardial pig-tail catheter and reversal of anticoagulation with protamine should be performed. After pericardial drainage, the patient needs to be monitored with the drain left in place usually for 24 h. In most cases, the bleeding stops spontaneously, but in some cases cardiac surgery is required, especially in the presence of a tear. It is important to be aware of the pos-

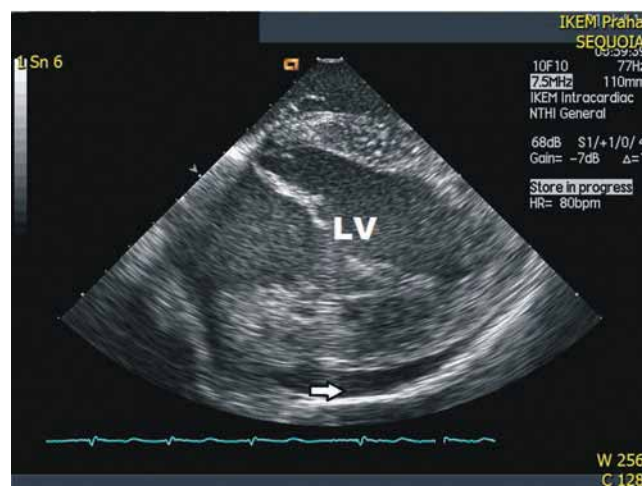


Fig. 2 – Pericardial effusion shown by ICE (arrow), which arose during isolation of right pulmonary veins. LV – left ventricle.

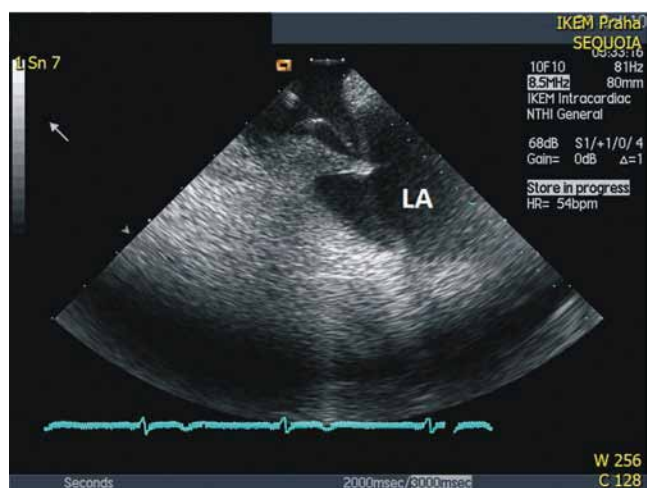


Fig. 3 – Transseptal puncture performed under ICE control. Image shows the needle engaging the fossa ovalis. LA – left atrium.

sibility of delayed tamponade and include this entity in differential diagnosis of hypotension hours or days after the procedure.

Minor pericardial effusion without acute hemodynamic impact may be a result of an inflammatory reaction due to applied radiofrequency current with reported overall incidence of 0.8% [4].

ICE has been reported to allow earlier detection of a pericardial effusion [22] (Fig. 2). From our experience we found that the routine use of ICE may also reduce the risk of cardiac tamponade [13]. ICE enables to perform transseptal puncture under visual control of the tip of the needle engaging the fossa ovalis (Fig. 3). LA mapping and ostia of pulmonary veins tagging could also be easily performed. Finally, ICE can be used to monitor the course of radiofrequency applications, the position and the contact of ablation catheter with the tissue and switch off current application whenever sudden tissue whitening or bursts of microbubbles are observed.

Vascular complications

Vascular complications are the most frequent complications of catheter ablation for AF. These include hematoma, retroperitoneal hematoma, pseudoaneurysm, arteriovenous fistula and hemothorax due to subclavian or internal jugular venous access. Higher incidence of vascular complications likely reflects the number and the size of venous sheaths deployed in the setting of intense anticoagulation prior to and following the ablation procedures. An adequate hemostasis following sheath removal is essential. Anticoagulation regimen in the peri-ablation period seems to be an important factor in the occurrence of vascular complications. In a study by Prudente et al., an aggressive anticoagulation protocol of enoxaparin (1 mg/kg × 10 doses) resulted in a higher incidence of vascular complications compared to low doses (0.5 mg/kg × 6 doses) (5.7% vs. 1.6%, $p < 0.03$) [23]. Many other studies have already shown that performing AF ablation on uninterrupted anticoagulation with warfarin compared with heparin “bridging” has emerged with favorable safety results [14,24–27].

Recently, other risk factors such as venous access gaining by less experienced fellows [28], and lower body weight [13] have been shown to increase vascular complication incidence. The diagnosis and the management of vascular complications are based on general approaches of adequate hemostasis. Most of vascular complications are managed conservatively; however, some vascular complications require surgical intervention.

Atrio-esophageal fistula

Atrio-esophageal fistula is the most serious potential complication. Although its occurrence is rare (0.1–0.25%) [3], its mortality rate is higher than 80% and survivors of this complication are often left with disability from cerebrovascular events. Cadaveric studies have elucidated the relationship between the posterior wall of the LA and esophagus. The esophagus frequently courses within 5 mm of the atrial endocardium at some point in its path. The variable amount of fibro-fatty tissue interposed between the atrium and esophagus can contain vagal nerves and esophageal arteries exposing these structures to potential injury from ablation [29]. The thickness of the fat pad separating the left atrium and esophagus is variable and dependent on age, gender, body weight and left atrial size [29,30]. Application of radiofrequency lesions to the posterior wall is the most important factor responsible for esophageal injury [31]. Ablation of persistent AF as compared with paroxysmal AF is also a risk factor for esophageal injury probably due to more extensive ablation in persistent AF [32]. Gilinov et al. observed that patients with lower body mass index are at a higher risk of esophageal injury [33].

Clinical manifestation of atrio-esophageal fistula occurs usually 2–4 weeks after the ablation procedure. The most common symptoms comprise dysphagia, odynophagia, septic fever, gastrointestinal bleeding and recurrent neurological events due to a massive air embolism. In case of suspicion on atrio-esophageal fistula, urgent cardiac CT or MR scan is recommended. Avoiding endoscopy examination is equally important, since insufflation of the esophagus with air may result in a large air embolus producing stroke or death. Once the fistula is confirmed, urgent surgery is needed.

Because atrio-esophageal fistula is a very serious complication, it is important to make every effort to prevent it. Strategies proposed to prevent esophageal injury during AF ablation include reduced power titration while ablating the posterior left atrium wall, limiting radiofrequency delivery time, using conscious sedation rather than general anesthesia for better pain perception, and monitoring intraprocedural esophageal position in relation to the posterior left atrium wall [34–37]. In this respect, ICE is very useful in real-time visualization of the esophagus. Others use real-time temperature monitoring within the esophagus during the procedure [38]. This is believed to minimize excessive temperature rise in the esophagus and decrease risk of development of the fistula. However, there is no clear proof that this strategy avoids the risk of atrio-esophageal fistula. Whether routinely prescription of proton pump inhibitors or H2 blockers reduce the risk of atrio-esophageal fistula is still not clear.

Pulmonary vein stenosis

Pulmonary vein (PV) stenosis was more frequent (up to 40%) when ablation targeted focal triggers within the PVs [39]. Saad et al. in their early series of catheter ablation between 1998 and 2002 reported an overall incidence of PV stenosis of 15.6% [40]. Subsequent use of ICE to monitor catheter tip position and tissue overheating resulted in abolition of the risk [13]. The current strategy of ablation at the PV ostia significantly decreased the incidence of PV stenosis (0.4–3.4%) [3,4]. The true incidence of PV stenosis is likely underestimated as patient imaging is not routinely performed in most electrophysiology laboratories. Although the precise pathophysiological mechanisms are still uncertain, a progressive vascular reaction including architectural remodeling, intimal proliferation, and fibrosis, as well as thrombus formation have been suggested [41,42].

Therefore, energy delivery distally within the PVs should be avoided. Because PVs anatomy is very variable, CT or MR imaging can help to clarify the anatomy of PVs. At our center we found ICE very helpful to visualize the ostia of PVs and prevent ablation inside PVs.

Clinical signs of significant PV stenosis are not specific and highly variable, and can range from asymptomatic in mild or moderate to severe presentation. They may include cough, dyspnea, hemoptysis, or recurrent pneumonia [40,43]. Symptoms usually develop several weeks to months after the procedure. Diagnosis can be confirmed by CT or MRI scans. Ventilation–perfusion scanning or transesophageal echocardiography with Doppler can also be used. The preferred therapy for severe (> 70%) symptomatic PV stenosis is PV balloon angioplasty or stenting [40,44,45]. However, restenosis can develop despite stent placement and it is estimated to be 44% to 70% [45–47].

Phrenic nerve injury

Phrenic nerve paresis, likely from direct thermal injury, has been described after RF ablation, cryoablation, ultrasound, and laser ablation. The right phrenic nerve can be affected during ablation near the right superior PV or within the superior vena cava, whereas, left phrenic nerve rarely affected during ablation within the LA appendage [24,48]. The use of balloon technologies carries substantially higher risk of this complication, since the balloon has to be pressed inside the ostium and may prolapse deeper into the right superior PV and cause the damage.

Symptoms are usually less pronounced (dyspnea, hiccups, cough, pain, pleural effusion, or atelectasis) and in most cases, phrenic nerve affliction recovers after several (typically within 6–12) months. Diagnosis is confirmed on fluoroscopy as unilateral diaphragmatic paralysis.

Strategies to prevent phrenic nerve injury include high output pacing at vulnerable sites and avoiding ablation at sites that stimulate the phrenic nerve.

Injury to the vagus nerve

Injury to the vagal esophageal plexus can occur during RF delivery to the posterior wall of the LA. This can lead

to pyloric spasm, gastric hypomotility, and a markedly prolonged gastric emptying time [49]. The common symptoms are abdominal bloating and discomfort occurring hours to days after the procedure [50,51]. Spontaneous recovery typically occurs but may require up to 12 months. Prevention involves the same strategy as prevention of esophageal injury.

Other complications

Other less frequent complications can also occur. These include atrioventricular block, sepsis, pericarditis, mitral valve trauma and circular catheter entrapment and acute coronary artery occlusion of the left circumflex coronary artery.

Experience of IKEM

Recently, we have published data on analysis of complications from our center [13]. The study included consecutive 1,192 AF ablation procedures in 959 patients. All procedures were ICE-guided and performed by open-irrigated tip catheter after switching from warfarin to heparin. The power mode was used with a preset power up to 25–30 W and down-regulation when the tip temperature of 40–42 °C was achieved. Constant irrigation flow of 15 ml/min (30 ml/min inside the coronary sinus) was used. Forty major complications (3.3%) during the procedure or within the 3-month follow-up were observed. No death or atrio-esophageal fistula occurred. Three patients (0.25%) had cardiac tamponade/hemopericardium and five patients (0.42%) had cerebrovascular embolic event. Vascular injury was the most frequent (2.3%) complication including 2 hemothorax, 2 retroperitoneal bleeding, 1 subclavian vein bleeding, 7 femoral arteriovenous fistulas, 4 femoral pseudoaneurysms and 12 groin bleeding. There were also 1 pericarditis, 1 atrioventricular block and 1 transient phrenic nerve paresis. Low body weight was the only significant risk factor with 0.8% increase of complication rate per 10 kg of body weight decrease ($p = 0.013$). A trend for increase in complication rate was also observed for advanced age, female gender, and complex procedure, i.e. that with more than simple PV isolation.

Conclusions

Catheter ablation is an effective treatment option for AF. Although there is a higher risk of major complications with this procedure, considerable progress in prevention of these events reduced the risk of their incidence. Physicians performing these procedures must be vigilant for complications and skilled in early treatment to increase the safety of AF ablation procedure. Equally important is the fact that many of complications may appear later after ablation, and therefore, every cardiologist should be aware and learn about their presentations and diagnosis.

Funding

This study was supported by a Research Grant No MZO 00023001 of the Ministry of Health of the Czech Republic.

References

- [1] H. Calkins, K.H. Kuck, R. Cappato, et al., 2012 HRS/EHRA/ECAS Expert Consensus Statement on Catheter and Surgical Ablation of Atrial Fibrillation: recommendations for patient selection, procedural techniques, patient management and follow-up, definitions, endpoints, and research trial design, *Europace* 14 (2012) 528–606.
- [2] R. Cappato, H. Calkins, S.A. Chen, et al., Worldwide survey on the methods, efficacy, and safety of catheter ablation for human atrial fibrillation, *Circulation* 111 (2005) 1100–1105.
- [3] R. Cappato, H. Calkins, S.A. Chen, et al., Updated worldwide survey on the methods, efficacy, and safety of catheter ablation for human atrial fibrillation, *Circulation. Arrhythmia and Electrophysiology* 3 (2010) 32–38.
- [4] E. Bertaglia, F. Zoppo, C. Tondo, et al., Early complications of pulmonary vein catheter ablation for atrial fibrillation: a multicenter prospective registry on procedural safety, *Heart Rhythm* 4 (2007) 1265–1271.
- [5] E. Arbelo, J. Brugada, G. Hindricks, et al., ESC-EURObservational Research Programme: the Atrial Fibrillation Ablation Pilot Study, conducted by the European Heart Rhythm Association, *Europace* 14 (2012) 1094–1103.
- [6] R. Cappato, H. Calkins, S.A. Chen, et al., Prevalence and causes of fatal outcome in catheter ablation of atrial fibrillation, *Journal of the American College of Cardiology* 53 (2009) 1798–1803.
- [7] F. Gaita, D. Caponi, M. Pianelli, et al., Radiofrequency catheter ablation of atrial fibrillation: a cause of silent thromboembolism? Magnetic resonance imaging assessment of cerebral thromboembolism in patients undergoing ablation of atrial fibrillation, *Circulation* 122 (2010) 1667–1673.
- [8] G.Y. Lip, R. Nieuwlaat, R. Pisters, et al., Refining clinical risk stratification for predicting stroke and thromboembolism in atrial fibrillation using a novel risk factor-based approach: the euro heart survey on atrial fibrillation, *Chest* 137 (2010) 263–272.
- [9] S. Dorbala, A.J. Cohen, L.A. Hutchinson, et al., Does radiofrequency ablation induce a prethrombotic state? Analysis of coagulation system activation and comparison to electrophysiologic study, *Journal of Cardiovascular Electrophysiology* 9 (1998) 1152–1160.
- [10] A.S. Manolis, H. Melita-Manolis, V. Vassilikos, et al., Thrombogenicity of radiofrequency lesions: results with serial D-dimer determinations, *Journal of the American College of Cardiology* 28 (1996) 1257–1261.
- [11] P.B. Sparks, S. Jayaprakash, J.K. Vohra, et al., Left atrial stunning following radiofrequency catheter ablation of chronic atrial flutter, *Journal of the American College of Cardiology* 32 (1998) 468–475.
- [12] K. Lemola, B. Desjardins, M. Sneider, et al., Effect of left atrial circumferential ablation for atrial fibrillation on left atrial transport function, *Heart Rhythm* 2 (2005) 923–928.
- [13] B. Aldhoun, D. Wichterle, P. Peichl, et al., Complications of catheter ablation for atrial fibrillation in a high-volume centre with the use of intracardiac echocardiography, *Europace* 2012 doi:10.1093/europace/eus304.
- [14] O.M. Wazni, S. Beheiry, T. Fahmy, et al., Atrial fibrillation ablation in patients with therapeutic international normalized ratio: comparison of strategies of anticoagulation management in the periprocedural period, *Circulation* 116 (2007) 2531–2534.
- [15] J.F. Ren, F.E. Marchlinski, D.J. Callans, et al., Increased intensity of anticoagulation may reduce risk of thrombus during atrial fibrillation ablation procedures in patients with spontaneous echo contrast, *Journal of Cardiovascular Electrophysiology* 16 (2005) 474–477.
- [16] L. Di Biase, J.D. Burkhardt, P. Mohanty, et al., Periprocedural stroke and management of major bleeding complications in patients undergoing catheter ablation of atrial fibrillation: the impact of periprocedural therapeutic international normalized ratio, *Circulation* 121 (2010) 2550–2556.
- [17] P. Santangeli, L. Di Biase, R. Horton, et al., Ablation of atrial fibrillation under therapeutic warfarin reduces periprocedural complications: evidence from a meta-analysis, *Circulation. Arrhythmia and Electrophysiology* 5 (2012) 302–311.
- [18] D. Lakkireddy, Y.M. Reddy, L. Di Biase, et al., Feasibility and safety of dabigatran versus warfarin for periprocedural anticoagulation in patients undergoing radiofrequency ablation for atrial fibrillation: results from a multicenter prospective registry, *Journal of the American College of Cardiology* 59 (2012) 1168–1174.
- [19] L.F. Hsu, P. Jais, M. Hocini, et al., Incidence and prevention of cardiac tamponade complicating ablation for atrial fibrillation, *Pacing and Clinical Electrophysiology* 28 (Suppl 1) (2005) S106–S109.
- [20] O.J. Eick, B. Gerritse, B. Schumacher, Popping phenomena in temperature-controlled radiofrequency ablation: when and why do they occur? *Pacing and Clinical Electrophysiology* 23 (2000) 253–258.
- [21] J.G. Andrade, P. Khairy, P.G. Guerra, et al., Efficacy and safety of cryoballoon ablation for atrial fibrillation: a systematic review of published studies, *Heart Rhythm* 8 (2011) 1444–1451.
- [22] T.J. Bunch, S.J. Asirvatham, P.A. Friedman, et al., Outcomes after cardiac perforation during radiofrequency ablation of the atrium, *Journal of Cardiovascular Electrophysiology* 16 (2005) 1172–1179.
- [23] L.A. Prudente, J.R. Moorman, D. Lake, et al., Femoral vascular complications following catheter ablation of atrial fibrillation, *Journal of Interventional Cardiac Electrophysiology* 26 (2009) 59–64.
- [24] F. Sacher, K.H. Monahan, S.P. Thomas, et al., Phrenic nerve injury after atrial fibrillation catheter ablation: characterization and outcome in a multicenter study, *Journal of the American College of Cardiology* 47 (2006) 2498–2503.
- [25] F. Abhishek, E.K. Heist, C. Barrett, et al., Effectiveness of a strategy to reduce major vascular complications from catheter ablation of atrial fibrillation, *Journal of Interventional Cardiac Electrophysiology* 30 (2011) 211–215.
- [26] J.J. Kwak, H.N. Pak, J.K. Jang, et al., Safety and convenience of continuous warfarin strategy during the periprocedural period in patients who underwent catheter ablation of atrial fibrillation, *Journal of Cardiovascular Electrophysiology* 21 (2010) 620–625.
- [27] A.A. Hussein, D.O. Martin, W. Saliba, et al., Radiofrequency ablation of atrial fibrillation under therapeutic international normalized ratio: a safe and efficacious periprocedural anticoagulation strategy, *Heart Rhythm* 6 (2009) 1425–1429.
- [28] T.S. Baman, K. Jongnarangsin, A. Chugh, et al., Prevalence and predictors of complications of radiofrequency catheter ablation for atrial fibrillation, *Journal of Cardiovascular Electrophysiology* 22 (2011) 626–631.
- [29] D. Sanchez-Quintana, J.A. Cabrera, V. Climent, et al., Anatomic relations between the esophagus and left atrium and relevance for ablation of atrial fibrillation, *Circulation* 112 (2005) 1400–1405.
- [30] N. Doll, M.A. Borger, A. Fabricius, et al., Esophageal perforation during left atrial radiofrequency ablation: Is the risk too high?, *The Journal of Thoracic and Cardiovascular Surgery* 125 (2003) 836–842.
- [31] M. Schmidt, G. Nolker, H. Marschang, et al., Incidence of oesophageal wall injury post-pulmonary vein antrum isolation for treatment of patients with atrial fibrillation, *Europace* 10 (2008) 205–209.
- [32] M. Martinek, G. Bencsik, J. Aichinger, et al., Esophageal damage during radiofrequency ablation of atrial fibrillation: impact of energy settings, lesion sets, and esophageal visualization, *Journal of Cardiovascular Electrophysiology* 20 (2009) 726–733.
- [33] A.M. Gillinov, G. Pettersson, T.W. Rice, Esophageal injury during radiofrequency ablation for atrial fibrillation, *The Journal of Thoracic and Cardiovascular Surgery* 122 (2001) 1239–1240.

- [34] M. Martinek, C. Meyer, S. Hassanein, et al., Identification of a high-risk population for esophageal injury during radiofrequency catheter ablation of atrial fibrillation: procedural and anatomical considerations, *Heart Rhythm* 7 (2010) 1224–1230.
- [35] J.F. Ren, D. Lin, F.E. Marchlinski, et al., Esophageal imaging and strategies for avoiding injury during left atrial ablation for atrial fibrillation, *Heart Rhythm* 3 (2006) 1156–1161.
- [36] S.M. Singh, A. d'Avila, S.K. Doshi, et al., Esophageal injury and temperature monitoring during atrial fibrillation ablation, *Circulation. Arrhythmia and Electrophysiology* 1 (2008) 162–168.
- [37] L. Di Biase, L.C. Saenz, D.J. Burkhardt, et al., Esophageal capsule endoscopy after radiofrequency catheter ablation for atrial fibrillation: documented higher risk of luminal esophageal damage with general anesthesia as compared with conscious sedation, *Circulation. Arrhythmia and Electrophysiology* 2 (2009) 108–112.
- [38] L.R. Leite, S.N. Santos, H. Maia, et al., Luminal esophageal temperature monitoring with a deflectable esophageal temperature probe and intracardiac echocardiography may reduce esophageal injury during atrial fibrillation ablation procedures: results of a pilot study, *Circulation. Arrhythmia and Electrophysiology* 4 (2011) 149–156.
- [39] I.M. Robbins, E.V. Colvin, T.P. Doyle, et al., Pulmonary vein stenosis after catheter ablation of atrial fibrillation, *Circulation* 98 (1998) 1769–1775.
- [40] E.B. Saad, A. Rossillo, C.P. Saad, et al., Pulmonary vein stenosis after radiofrequency ablation of atrial fibrillation: functional characterization, evolution, and influence of the ablation strategy, *Circulation* 108 (2003) 3102–3107.
- [41] W.C. Yu, T.L. Hsu, C.T. Tai, et al., Acquired pulmonary vein stenosis after radiofrequency catheter ablation of paroxysmal atrial fibrillation, *Journal of Cardiovascular Electrophysiology* 12 (2001) 887–892.
- [42] G.W. Taylor, G.N. Kay, X. Zheng, et al., Pathological effects of extensive radiofrequency energy applications in the pulmonary veins in dogs, *Circulation* 101 (2000) 1736–1742.
- [43] D.L. Packer, P. Keelan, T.M. Munger, et al., Clinical presentation, investigation, and management of pulmonary vein stenosis complicating ablation for atrial fibrillation, *Circulation* 111 (2005) 546–554.
- [44] B. Baranowski, W. Saliba, Our approach to management of patients with pulmonary vein stenosis following AF ablation, *Journal of Cardiovascular Electrophysiology* 22 (2011) 364–367.
- [45] T. Neumann, M. Kuniss, G. Conradi, et al., Pulmonary vein stenting for the treatment of acquired severe pulmonary vein stenosis after pulmonary vein isolation: clinical implications after long-term follow-up of 4 years, *Journal of Cardiovascular Electrophysiology* 20 (2009) 251–257.
- [46] T. Arentz, N. Jander, J. von Rosenthal, et al., Incidence of pulmonary vein stenosis 2 years after radiofrequency catheter ablation of refractory atrial fibrillation, *European Heart Journal* 24 (2003) 963–969.
- [47] L. Di Biase, T.S. Fahmy, O.M. Wazni, et al., Pulmonary vein total occlusion following catheter ablation for atrial fibrillation: clinical implications after long-term follow-up, *Journal of the American College of Cardiology* 48 (2006) 2493–2499.
- [48] R. Bai, D. Patel, L. Di Biase, et al., Phrenic nerve injury after catheter ablation: should we worry about this complication?, *Journal of Cardiovascular Electrophysiology* 17 (2006) 944–948.
- [49] D. Shah, J.M. Dumonceau, H. Burri, et al., Acute pyloric spasm and gastric hypomotility: an extracardiac adverse effect of percutaneous radiofrequency ablation for atrial fibrillation, *Journal of the American College of Cardiology* 46 (2005) 327–330.
- [50] C.F. Pisani, D. Hachul, E. Sosa, et al., Gastric hypomotility following epicardial vagal denervation ablation to treat atrial fibrillation, *Journal of Cardiovascular Electrophysiology* 19 (2008) 211–213.
- [51] T.J. Bunch, K.A. Ellenbogen, D.L. Packer, et al., Vagus nerve injury after posterior atrial radiofrequency ablation, *Heart Rhythm* 5 (2008) 1327–1330.